

## PROLIFERATION MARKERS, —AgNORs, CORRELATION WITH GRADE OF INVASIVE DUCTAL CARCINOMA OF BREAST

AHTESHAM K., JAFFER R., IMRAN A.A., SALARIA S. M. AND HASEEB M.T.  
 Department of Pathology, Postgraduate Medical Institute, Ameer-ud-Din Medical College,  
 University of Health Sciences, Lahore, Pakistan

### ABSTRACT

**Background and Objectives:** Breast cancer is the most common malignancy and a leading cause of death in women. The objectives of this study were to compare the argyrophilic nucleolar organizer region (AgNOR) parameters and estrogen receptor status with grades of invasive ductal carcinoma of breast.

**Methods:** 50 cases of invasive ductal carcinoma of breast diagnosed on trucut, core biopsy/ incision/ excision was collected from Lahore General Hospital, Lahore. Hematoxylin and eosin, AgNOR and estrogen staining was done. AgNOR parameters and ER status were compared with grades of invasive ductal carcinoma.

**Results:** The mean age of the patients was 46.84 years  $\pm$  11.8 SD. A significantly greater proportion ( $p < 0.01$ ) of grade III tumors showed a variation in AgNOR size of 3+ when compared with grade II tumors. AgNOR dispersion was predominantly of 3+ in grade II tumors, whereas all the grade III tumors had 3+ AgNOR dispersion. However, the difference was not statistically significant. All estrogen receptor positive tumors were of low grade as compared to ER -ve, and the difference was statistically significant.

**Conclusion:** It is concluded that AgNOR size, dispersion and ER status correlate well with Bloom and Richardson grade of invasive ductal carcinoma of breast.

**Key words:** Argyrophilic Nucleolar Organizer Regions, Breast carcinoma, Bloom and Richardson Grade, Estrogen receptor.

### INTRODUCTION

Breast cancer is the most common malignancy and a leading cause of death in women in middle age.<sup>1</sup> Carcinoma breast is hormone dependent.<sup>2</sup> Mostly estrogen receptor positive tumors are of low grade, whereas ER -ve tumors are high grade.<sup>3</sup>

The prognosis of breast carcinoma depends on several morphological and endocrinal variables. These include tumor size, grade, lymph node metastasis, tissue receptor status, HER2, p53, Ki67 and AgNORs.<sup>4,5</sup>

The nucleolar organizer regions are chromosomal loops of DNA involved in ribosomal synthesis. These NORs are located on each of the short arms of the chromosomes 13, 14, 15, 21 and 22. These proteins are identified by a silver colloid staining technique and visualized as dark intranuclear dots under the microscope. They are fine and dispersed singly in benign tumors. In malignant tumors, the dots are coarse and may form clusters.<sup>6</sup>

AgNOR is helpful in discriminating benign from malignant disease or indistinguishing between low and high grade malignancy.<sup>5</sup> AgNORs can prove to be useful, especially in situations in which tissue is insuffi-

cient for flowcytometry such as small biopsies and limited needle aspirates.<sup>7</sup> Study of the proliferation markers help in the proper diagnosis of different breast lesions which lie in the gray zone on routine histopathology. Special techniques for example morphometry, DNA ploidy and immunohistochemical studies against various antigens are used to differentiate premalignant lesions like fibrocystic disease with epitheliosis, atypical ductal hyperplasia, atypical lobular hyperplasia, sclerosing adenosis and carcinoma in situ.<sup>8</sup>

Statistically significant difference in the mean number of AgNORs was found between normal, ordinary hyperplasia and neoplastic breast lesions.<sup>9</sup>

However, AgNOR counting is a tedious process. Over/under staining and variability in section thickness can lead to difficulties in counting the dots.<sup>10</sup> Therefore alternate methods have been used to assess AgNORs. These include AgNOR variation in size and dispersion.<sup>11</sup> These parameters have been used to differentiate benign from malignant lesions in breast,<sup>9</sup> prostate,<sup>12</sup> pleural and peritoneal effusions,<sup>13,14</sup> urinary bladder,<sup>15</sup> cervix,<sup>16</sup> brain,<sup>17</sup> liver,<sup>18</sup> benign lesions of

oral cavity and larynx from squamous cell carcinoma,<sup>19</sup> benign and malignant salivary gland tumors,<sup>20</sup> as well as in reactive lymphocytosis from acute and chronic leukemias.<sup>21</sup>

**OBJECTIVES**

To compare the AgNOR size, dispersion and ER status with grades of invasive ductal carcinoma of breast.

**PATIENTS AND METHODS**

In this comparative and descriptive study fifty specimens of invasive ductal carcinoma breast was collected from Lahore General Hospital, Lahore. Hematoxylin and Eosin staining, AgNOR and ER staining were done. Histological diagnosis and grading was done on H&E stained slides. For AgNOR staining the method used by Khalid et al (1996) was followed.<sup>13</sup> The nuclei were stained light yellow and AgNORs were visualized as brown black discrete dots of variable size within the nuclei.

Variation in AgNOR size and dispersion were graded according to Khan et al (2006),<sup>11</sup> as follows: **Size Variation** 0 = More or less uniform, 1+ = Two different sizes, 2+ = More than two different sizes but not those of 3+, 3+ = All grades and sizes including too minute to be counted. **Dispersion:** 0 = Limited to nucleoli, 1+ = Occasional dispersion outside nucleoli, 2+ = Moderate dispersion outside nucleoli, 3+ = Widely dispersed throughout the nucleus.

The data was analyzed using SPSS 21.0. The variation in AgNOR size, dispersion and ER staining in grade II and grade III tumors was compared using chi square test.  $p \leq 0.05$  was considered significant for statistical analysis.

**RESULTS**

This study included 50 cases of invasive ductal carcinoma of the breast. Histological diagnosis and grading of the tumor was done on H&E stained slides using Nottingham Modification of Bloom and Richardson grading system (Fig. 1). AgNOR staining was carried out on all cases, and variation in AgNOR size and dispersion were determined (Fig. 2). Estrogen receptor staining was done on all cases and ER status was determined.

The ages of the patients ranged from 24 – 85 years with a mean of 46.84 years  $\pm$  11.8.

The duration of symptoms ranged from 2-12 months. The mean duration of symptoms was 4.62 months. Maximum number of patients had duration of symptoms from 4 – 5 months.

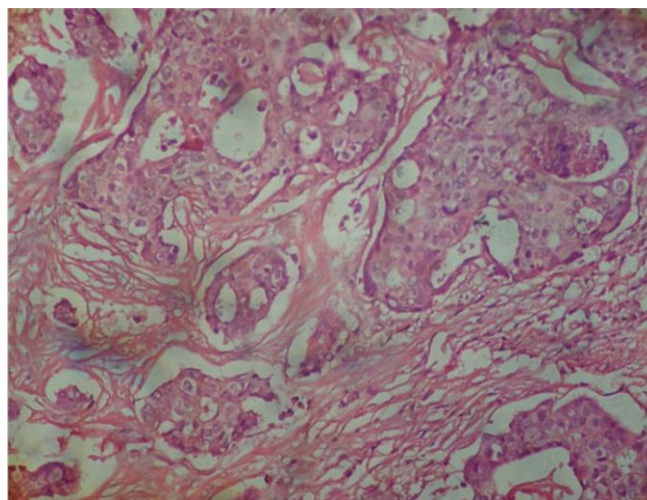
There were 37 cases (74%) of grade II tumors, 13 cases (26%) of grade III tumor.

A significantly greater proportion ( $p < 0.01$ ) of grade III tumors showed a variation in AgNOR size of 3+ when compared with grade II tumors (Table 1).

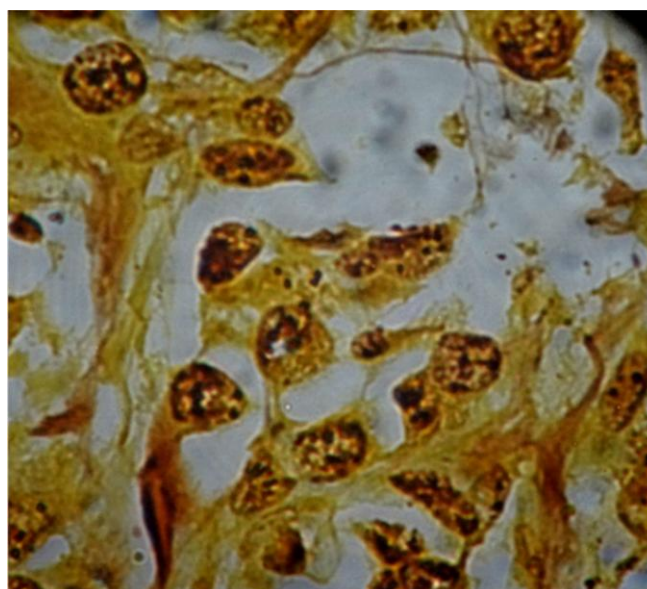
**Table 1:** Comparison of AgNOR size in different grades of tumor.

Grade	No. of Cases with AgNOR Size		Total
	2+	3+	
II	20	17	37
III	1	12	13
Total	21	29	50

$P < 0.01$



**Fig. 1:** Photomicrograph of a section of invasive ductal carcinoma breast-grade II (H&E, x400).



**Fig. 2:** Photomicrograph of a section of invasive ductal carcinoma breast grade III (AgNOR staining x1000).

AgNOR dispersion was predominantly of 3+ in grade II tumors, whereas all the grade III tumors had 3+ AgNOR dispersion. However, the difference was not statistically significant (Table 2).

**Table 2:** Comparison of AgNOR dispersion in different grades of tumor.

Grade	No. of Cases with AgNOR Dispersion		Total
	2+	3+	
II	10	27	37
III	0	13	13
Total	10	40	50

P = NS

Out of 27 ER-ve cases 14 were of grade II and 13 were of grade III. All the 23 ER+ cases were of grade II. The difference was statistically significant (p = 0.001), (Table 3).

**Table 3:** Comparison of ER status with grade of tumor.

ER status	Grade		Total
	II	III	
+ve	23	0	23
-ve	14	13	27
Total	37	13	50

P = 0.001

**DISCUSSION**

As many as 59% breast cancer cases are found in premenopausal women. It is the most frequently recorded malignancy and a leading cause of cancer morbidity and mortality in our population.<sup>22,23</sup>

Invasive ductal carcinoma is the most common form of breast cancer. Histological diagnosis and grading was done on H&E stained slides using Nottingham Modification of Bloom and Richardson grading system.<sup>24</sup> AgNOR and ER staining was also done on all the cases. Variation in AgNOR size, dispersion and ER status were determined.

The ages of the patients ranged from 24 – 85 years with a mean age of 46.84 years ± 11.8 SD. This is in accordance with the study conducted at Institute of Nuclear Medicine and Oncology, Lahore, Pakistan.<sup>25</sup>

In the present study, the duration of symptoms ranged from 2 – 12 months. The mean duration of symptoms was 4.62 months and maximum number of cases had duration of symptoms of 4 to 5 months. In

most of our population the tumors are already of large size when women first come to the doctor.<sup>23</sup>

There were 37 cases of grade II tumors, and 13 were of grade III.

Variation in AgNOR size and dispersion were graded according to Khan et al (2006).<sup>11</sup>

In this study, significantly greater proportion (p<0.01) of grade III tumors showed a variation in AgNOR size of 3+ when compared with grade II tumors (Table 1). Variation in AgNOR size of higher grade has also been reported in other tumors as well. Study conducted by Khan et al (2008), showed variation in AgNOR size in grade II tumors of transitional cell carcinoma of urinary bladder was predominantly of 2+, while in grade III tumors it was predominantly 3+. Similarly, study conducted by Bukhari et al (2007), showed statistically significant difference between the variations of AgNOR dot size in different grades of astrocytoma.<sup>26,17</sup>

AgNOR dispersion was predominantly of 3+ in grade II tumors, whereas all the grade III tumors had 3+ AgNOR dispersion. However, the difference was not statistically significant (table 2). Khan et al (2008), in their study on transitional cell carcinoma of urinary bladder found statistically significant high grade of AgNOR dispersion in grade III tumors than grade II tumors. AgNOR size is more useful parameter than AgNOR dispersion in assessing aggressiveness of invasive ductal carcinoma of breast.<sup>26</sup>

In this study, out of 27 ER –ve cases 14 cases were of grade II and 13 were of grade III. All the 23 ER+ve cases were of grade II. The difference was statistically significant (p=0.001, table 3). In the study conducted by Mudduwa (2009), 151 breast cancer cases were included. His study showed an inverse relationship between Nottingham modification of Bloom and Richardson grade and hormone receptor status.<sup>27</sup>

Further studies on larger number of cases are required to confirm these findings. Moreover, studies may be carried out on carcinoma of special type (lobular, tubular, medullary, mucinous etc.) and then these can be compared with that of invasive ductal carcinoma.

It is **concluded** that AgNOR size, dispersion and ER status correlate well with histological grade. Therefore, AgNOR staining which is much cheaper, can be a useful tool to discriminate between low and high grade tumors, and can guide in management of patients.

**ACKNOWLEDGEMENTS**

We are extremely thankful to the administration of Postgraduate Medical Institute, Lahore and Lahore General Hospital, Lahore for supporting and facilitating us to conduct this study.

**Author’s Contribution**

KA: Did the research work and wrote the article. RJ:

Helped in providing material for research and in doing research. AAI: Helped in research work and writing the article. SMS: Helped in doing the research. MTH: Helped in checking the bibliography.

**REFERENCES**

1. Ahmadi AS, Mahdipour L, Payandeh M, Sadeghi M. Epidemiology, pathology and histochemistry features in women with breast cancer. *Am J Cancer Prev.* 2015; 3: 54-7.
2. Ahtesham K, Jaffer R, Imran AA, Salaria SM, Hasan M. Correlation of Mean Argyrophilic Nucleolar Organizer Regions and Agnor Proliferation Index with Estrogen Receptor Status in Carcinoma of breast. *Biomedica,* 2015; 31: 296-299.
3. Lester SC. The Breast. In: Kumar V, Abbas AK, Fausto N, editors. *Pathologic basis of disease.* 9<sup>th</sup> Ed. Robins and Cotran. Philadelphia. Elsevier; 2015: pp 1065-1095.
4. Madani SH, Payandeh M, Sadeghi M, Motamed H, Sadeghi E. The correlation between Ki-67 with other prognostic factors in breast cancer: A study in Iranian patients. *Indian J Med Paediatr Oncol.* 2016; 37: 95-99.
5. Derenzini M, Ceccarelli C, Santini D, Taffurelli M, Treré D. The prognostic value of the AgNOR parameter in human breast cancer depends on the pRb and p53 status. *Clin Pathol.* 2004; 57: 755-761.
6. Ahtesham K, Jaffer R, Imran AA, Hassan M, Salaria SM. Correlation of mAgNOR and pAgNOR with grade of invasive ductal carcinoma of breast. *Biomedical.* 2015; 1: 18-21.
7. Mourad WA, Erkman-Balis B, Livingston S, Shoukri M, Cox CE, Nicosia SV, Rowlands DT et al. Argyrophilic nucleolar organizer regions in breast carcinoma. Correlation with DNA flow cytometry, histopathology, and lymph node status. *CA: A Cancer J Clin.* 1992; 69: 1739-1744.
8. Manna AK, Pathak S, Sarkar DK. Role of proliferative markers in Breast lesions. *Ind J Surg.* 2010; 72: 57-61.
9. Mijovic Z, Stefanovic N, Mihailovic D, Kostov M. Quantification of Argyrophilic Nucleolar Organizer Regions in estrogen receptor positive and estrogen receptor negative ductal breast carcinomas. *Facta Universitatis,* 2006; 13: 65-69.
10. Ansari HA, Mehdi G, Maheshwari V, Siddiqui SA. Evaluation of AgNOR scores in aspiration cytology smears of breast tumors. *J Cytol.* 2008; 25: 100-104.
11. Khan SA, Chaudhry NA, Khalid AW, Akhtar GN, Ibnerasa SN. Patterns of Argyrophilic nucleolar organizer regions in pleural and peritoneal effusions. *J Coll Physicians Surg Pak.* 2006; 16: 412-5.
12. Ahsan S, Khan SA, Chaudhry NA. Argyrophilic nucleolar organizer regions (AgNORs) in nodular hyperplasia and carcinoma of the prostate. *Pak J Pathol.* 1992; 3: 81-83.
13. Khalid AW, Khan SA, Chaudhry NA, Tayyab M, Tehseen S. Silver Staining Nucleolar Organizer Region (AgNOR) counts in Benign and malignant effusions. *Pak Postgraduate Med J.* 1996; 7: 54-56.
14. Ibnerasa SN, Chaudhry NA, Khan SA. AgNOR proliferative index in malignant pleural and peritoneal effusions. *Int J Pathol.* 2005; 3: 86-90.
15. Khan AH, Khan SA, Chaudhry NA, Tayyab M. Comparison of argyrophilic nucleolar organizer regions (AgNORs) with proliferating cell nuclear antigen (PCNA) in different grades of transitional cell carcinoma of urinary bladder. *Annals,* 2007; 13: 186-190.
16. Alarcon-Romero LC, Illades-Aguar B, Flores-Alfaro E, Teran-Porcayo MA, Antonio-Vejar V, Reyes-Maldonado E. AgNOR polymorphism association with squamous intraepithelial lesions and invasive carcinoma with HPV infection. *Salud Publica Mex.* 2009; 51: 134-140.
17. Bukhari MH, Niazi S, Khan SA, Hashmi I, Perveen S, Qureshi SS et al. Modified method of AgNOR staining for tissue and interpretation in histopathology. *Int J Exp Pathol.* 2007; 88: 47-53.
18. Parveen S, Bukhari MH, Khan SA, Naveed IA, Chaudhry NA, Tahseen, M. AgNOR stain in normal, cirrhotic and carcinomatous liver. *Biomedica,* 2006; 22: 59-61.
19. Saluja M, and Vandana KL. The diagnostic and prognostic implications of silver binding nucleolar organizer regions in periodontal lesions. *Ind J Dent Res.* 2008; 19: 36-41.
20. Eslami B, Rahimi H, Rahimi F, Khiavi MM, Ebadifar A. Diagnostic value of silver nitrate staining for nucleolar organizer regions in selected head and neck tumors. *J Cancer Res Ther.* 2006; 2: 129-131.
21. Tasneem T, Rashid A, Akhtar S, Ahmad S. Argyrophilic Nucleolar Organizer Regions (AgNOR) in lymphocytic leukemia. *Annals,* 2001; 7: 288-290.
22. Jamal S, Moghal S, Mamoon N, Mushtaq S, Luqman M, Anwar M. The patterns of malignant tumors: Tumor registry data analysis, AFIP, Rawalpindi Pakistan (1992-2001). *J Pak Med Assoc.* 2006; 56: 359-62.
23. Ahmed Z, Khurshid A, Qureshi A, Idrees R, Asghar N, Kayani N. Breast carcinoma grading, estimation of tumor size, axillary lymph node status, staging and Nottingham Prognostic Index scoring on mastectomy specimens. *Ind J Pathol & Microbiol.* 2009; 52: 477-481.
24. Bloom HJG, Richardson WW. Histological grading and prognosis in breast cancer. *Br J Cancer.* 1957; 11 (3): 359-377.
25. Khokher S, Mahmood S, Khan SA. Response to neo-adjuvant chemotherapy in patients with advanced breast cancer: A local hospital experience. *Asian Pacific J Cancer Prev.* 2010; 11: 303-308.
26. Khan AH, Khan SA, Chaudhry NA, Tayyab M. Argyrophilic nucleolar organizer regions (AgNOR) pattern in different grades of transitional cell carcinoma of urinary bladder. *Annals of KEMU,* 2008; 14: 86-89.
27. Mudduwa LKB. Quick score of hormone receptor status of breast carcinoma: Correlation with the other clinicopathological prognostic parameters. *Ind J Pathol Microbiol.* 2009; 52: 159-163.