

PATTERN OF BENIGN MORPHOLOGICAL MYOMETRIAL LESIONS IN TOTAL ABDOMINAL HYSTERECTOMY SPECIMENS

RAHAT SARFRAZ,¹ M. SARFRAZ AHMED,² FARRUKH KAMAL³ AND AMEENA AFSAR³

¹Department of Pathology, Allama Iqbal Medical College, ²Department of Surgery, Services Institute of Medical Sciences and ³Department of Pathology, Fatima Jinnah Medical College, Lahore

ABSTRACT

Introduction: Hysterectomy is one of the most common major surgical procedure performed all over the world. Indications for total abdominal hysterectomy include dysfunctional uterine bleeding, leiomyoma, adenomyosis, chronic pelvic pain and pelvic inflammatory disease. Other causes include endometrial hyperplasia, cervical intraepithelial neoplasia, invasive cancer and endometrial malignancy. Hysterectomy specimens contribute a major component of histopathological work in Pathology laboratories. The present study was undertaken in Pathology department, Allama Iqbal Medical College, Lahore to find out the morphology and frequency of different benign histopathological lesions in myometrium of uterus in total abdominal hysterectomy specimens.

Subjects and Methods: A descriptive case series study of one hundred total abdominal hysterectomy specimens was carried out in Allama Iqbal Medical College, Lahore.

Results: One hundred total abdominal hysterectomy specimens were studied. The ages of the patients ranged from 30 – 69 years with maximum (73%) cases in 40 – 49 years age group. The commonest presenting complaint was menorrhagia (68%). The two benign histopathological lesions in myometrium were leiomyoma and adenomyosis. Myometrium revealed leiomyoma in 69% cases and foci of adenomyosis in 47% cases.

Conclusion: The commonest benign histopathological lesion in myometrium was leiomyoma (69%) followed by adenomyosis (47%).

Key Words: Hysterectomy, Benign lesions, Leiomyomas, Morphology, Uterus.

INTRODUCTION

Hysterectomy is one of the frequently performed procedures all over the world, accounting for 500,000 to 600,000 procedures annually in the United States.¹ There has been no recent population based study in Pakistan providing estimates of hysterectomy prevalence although there has always been concern about the high rates of this procedure.² Indications for hysterectomy for benign diseases are dysfunctional uterine bleeding (DUB), fibroids, prolapse, endometriosis, chronic pelvic pain and pelvic inflammatory disease.³ The route of hysterectomy is determined by the skill, experience and preference of operating gynaecologist.⁴ Total abdominal hysterectomy is the procedure of choice in conditions other than utero – vaginal prolapsed.⁵

Hysterectomy specimens constitute a major component of histopathological work in our laboratories. The present study was under taken to find out the frequency and morphology of different benign histopathological lesions in myometrium of total abdominal hysterectomy specimens.

MATERIAL AND METHODS

A descriptive case series study of one hundred total abdominal hysterectomy specimens was carried out

in Pathology department Allama Iqbal Medical College, Lahore. The sampling was convenient and purposive. Total abdominal hysterectomy specimens for non malignant causes were included while caesarean and vaginal hysterectomies were excluded.

Data Collection and Analysis Procedure

Patients' data and detailed gross examination of specimens was recorded on proforma. Representative sections were taken, slides prepared, microscopic examination done and findings were recorded. Collected data from the pre-designed Proforma was entered into SPSS (Statistical package for social sciences) version 10.0 and analyzed descriptively. In our descriptive analysis count and percentages were calculated for qualitative variables i.e leiomyoma, adenomyosis. While means and Standard deviations were calculated for quantitative variables i.e patients' age, length of uterus, breadth of uterus, myometrial thickness, etc.

RESULTS

The main objective of the study was to find out the frequency of various benign histopathological lesions in uterine myometrium and to study the morphological pattern of these lesions in a total of

one hundred abdominal hysterectomy specimens.

To meet these objectives, collected data was analysed accordingly into different tables and figures.

The ages of the patients ranged from 30 – 69 years with a maximum number of 73 women (73%) in 40 – 49 years of age group (Fig 1). Ninety group (Fig 1). Ninety seven women (97%) were married, out these 92 (94.8%) were parous. The parity ranged from 1 – 10 children with an average of 4 children. The commonest presenting complaint of the patients was menorrhagia (68%). Other less common complaints were dysmenorrhea (22%) and menometorrhagia (10%).

Table 1: Gross dimensions of uterus.

Gross dimensions	Minimum (cm)	Maximum (cm)	Mean (cm)	Standard deviation (cm)
Length of uterus	7	18	11.67	2.217
Breadth of uterus	4	14	7.7	2.3668
Width of uterus	2	9	4.38	1.8424

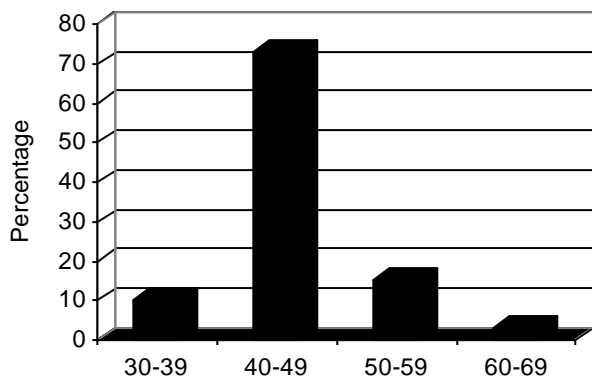


Fig. 1: Ages of patients undergoing hysterectomy.

The gross dimensions of uterus are given in Table 1. Myometrial thickness ranged from 2-10 cm with a mean of 3.5 cm. On gross examination fibroid like growths were seen grossly in 69 cases (69%).

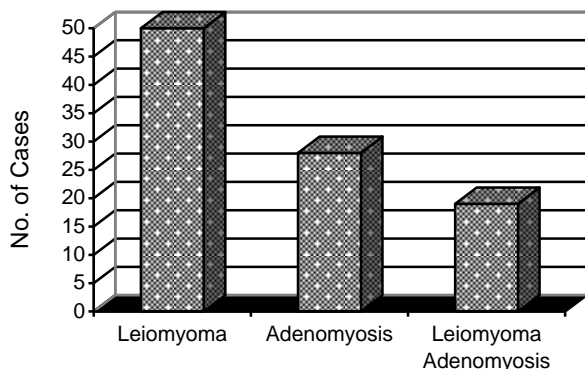


Fig. 2: Microscopic myometrial pathology.

Microscopic examination of sections from myometrium confirmed the histology of leiomyoma in all 69 cases (69%) showing fibroid like growth on gross examination. Among these 69 cases of lei-

Table 2: Dimensions of leiomyomas.

Dimensions	Minimum (cm)	Maximum (cm)	Mean (cm)	Standard deviation
Length	1	15	5.05	3.537
Width	1	12	2.87	2.378

omyomas, 50 showed leiomyomas alone whereas 19 cases showed leiomyomas along with adenomyosis (Fig. 2). The leiomyomas ranged in numbers from 1–8. Single leiomyoma was seen in 27 cases. Multiple leiomyomas were seen in 42 out of 69 cases. Location of leiomyomas is given in Fig. 3. Maximum leiomyomas, 43 of 69 cases were intramural. The dimensions of leiomyomas are given in Table 2. Adenomyosis alone was seen in 28 cases (28%) and combined with leiomyomas in 19 cases (19%). In total, adenomyosis was seen in 47 cases (47%) (Fig. 2).

From above data, descriptive statistics was calculated for all quantitative variables including means and standard deviations. It was found that minimum patient’s age was 35 years and maximum 60 years with mean and SD of 44.58 ± 4.137 . Similarly, minimum and maximum length of uterus was 7.0 and 18.0 cm respectively with mean and SD of 11.670 ± 2.2170 . Breadth of uterus was 4.0 to 14.0 cm with mean and SD of 7.70 ± 2.367 , width of uterus was 1.5 to 10 cm with mean and SD of 4.380 ± 1.8424 . Myometrial thickness was 2.0 to 8.0 cm with mean and SD of 3.559 ± 1.040 , the number of leiomyoma was 1 to 8 with mean and SD of 1.83 ± 1.599 .

DISCUSSION

The present prospective study was conducted with an aim to find the frequency of benign morphological changes in myometrium of uterus in cases of total abdominal hysterectomy specimens.

A total of 100 abdominal hysterectomy specimens for non malignant causes were included in the study. The ages of the patients undergoing hysterectomy in the present study ranged from 35 to 69 years with a mean of 44.58. Nearly the same age range of the patients undergoing hysterectomy was previously reported.⁶ The maximum number of patients i.e 73 (73%) undergoing hysterectomy in the present study were in 40 – 49 years age group. The

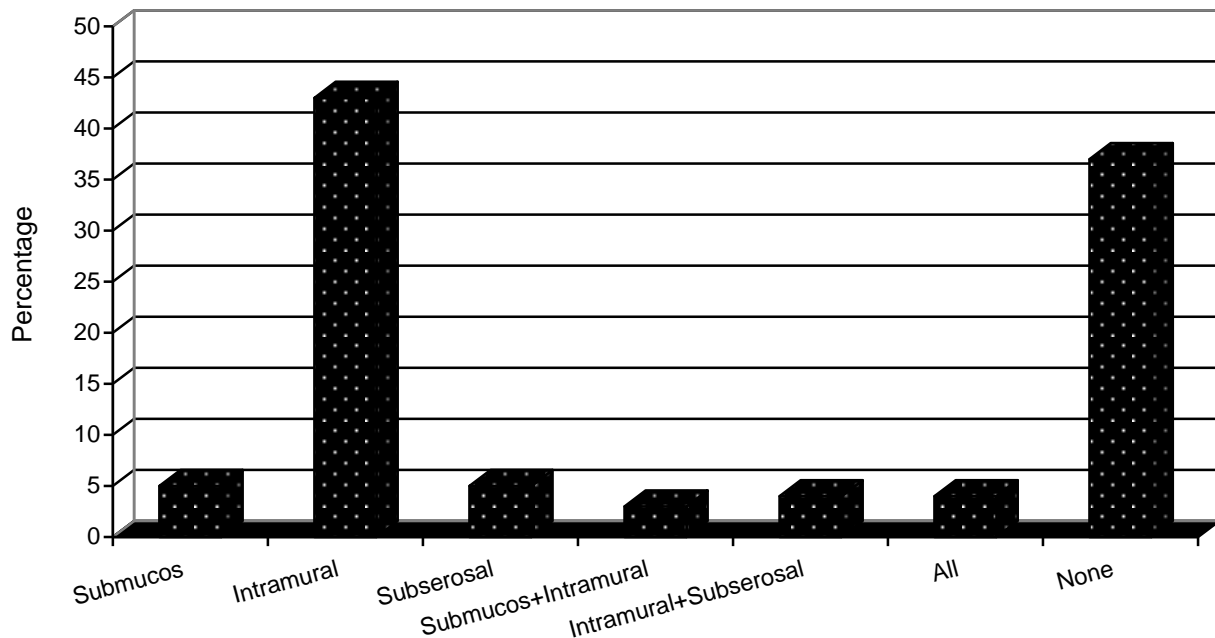


Fig. 3: Location of Leiomyomas.

similar results were found by various other authors in their studies.^{1,2,6,7}

Leiomyoma is the commonest uterine tumour and it is considered that neoplasms of uterus are almost all leiomyomas.⁸ Uterine leiomyomata, commonly known as fibroids are benign smooth muscle tumours of the uterus. They have been identified as one of the leading cause of hospitalisation for gynaecological disorders and hysterectomy in the USA.⁸ These are the primary indications for nearly 600,000 hysterectomies performed each year in the United States, and 37,000 myomectomies performed annually.⁹

In our study, also the commonest (69%) benign myometrial lesion was leiomyoma. Among these, 50% were leiomyomata alone and 19% were accompanied with adenomyosis. This relatively high frequency of leiomyomas in the present study is consistent with many other studies on the subject with some variation in their percentages.^{5,8,6} Akhter et al³ found a very high (90.69%) frequency of leiomyomas in their patients underwent hysterectomies.

In the present study, the sizes of leiomyomas ranged from 0.5 to 15 cm in width and 0.5 to 12 cm in length. Kamal et al⁸ also found such a size variation in their study. Leiomyomas vary in size from microscopic to multinodular uterine tumours that may weigh more than 50 pounds and literally fill the patient's abdomen and produce clinical signs and symptoms.¹¹

In the present study 42 cases out of a total of 69

cases of leiomyomas showed multiple leiomyomas (60.87%). Kamal et al⁸ had similar finding in their study. Other studies also give a higher occurrence of multiple leiomyomas rather than single leiomyoma.^{12,13}

Adenomyosis uteri is a pathological entity characterized by the presence of endometrial glands and stroma embedded within the myometrium without apparent contact with the endo-myometrial junction.¹⁴ According to another local study¹⁵ there is a wide variation in the reported prevalence of adenomyosis as a result of different classifications used, which are based on the invasion of myometrium by glands and stroma either in terms of proportion of uterine wall thickness or absolute measurement.¹⁵ Criteria for the diagnosis of adenomyosis varies widely in practice. The standard criterion used in the diagnosis of adenomyosis is the finding of endometrial glands and stroma more than one low-power field (2.5 mm) from the basalis layer of the endometrium.¹⁶ As the diagnosis of adenomyosis is based on histological examination the condition is best described in women at the time of hysterectomy.¹⁴

In the present study 47% of specimens showed adenomyosis in the body of uterus. Twenty eight percent (28%) of these showed adenomyosis alone and 19% showed adenomyosis with leiomyomas. The reported frequency of adenomyosis in various studies ranged from 9.81% –56.5%.^{6,13-15} However, a very high frequency of adenomyosis (83%) is reported by Akhter et al in their study.³ In another

study conducted by Ahsan et al adenomyosis was found to be the commonest histopathological finding.⁷ According to Parazzini et al¹⁷ adenomyosis is common in women who undergo hysterectomy and that it is more frequent in women reporting induced abortions, dysmenorrhea and chronic pelvic pain.

According to Bergholt et al,¹⁴ as there is a great variation in the use and indication for hysterectomy on national as well as international levels, populations of women undergoing hysterectomy in different regions are heterogeneous and consequently subject to demographic variation. This fact is probably responsible for some of the great variation seen in the prevalence of adenomyosis at hysterectomy worldwide. In our study 19% hysterectomy specimens showed both adenomyosis and leiomyoma combined in the body of uterus. Other studies also show coexistence of both these pathologies in their studies.^{15,4,6,17}

The present study **concluded** that the commonest benign histopathological lesion in the myometrium of uterus in total hysterectomy specimens is leiomyoma (69%) followed by adenomyosis (47%).

REFERENCES

1. Mc Pherson K, Metcalfe MA, Herbert A, Maresh M, Casbard A, Hargreaves J et al. Severe Complications of hysterectomy: The VALUE study. *Br J Obstet and Gynaecol* 2004; III: 688 – 94.
2. Bashir R, Parveen Z, Sultana R, Khan B. A two years audit of complications of Hysterectomy at Ayub Teaching Hospital Abbottabad. *J Ayub Med Coll Abbottabad* 2005; 17: 47-9.
3. Akhtar S, Amjad T, Qureshi N. Confirmation of the preoperative diagnosis for Hysterectomy. *JCPSP* 1999; 9: 483-85.
4. Daniel JF, Anderson TL, Astuto J. Laproscopic hysterectomy and health care in America-Finding the balance between costs and outcomes. 2006. Available from: www.OBGYN.Net/hysterectomy-alternative.
5. Shergill SK, Shergill HK, Gupta M, Kaur S. Clinicopathological study of hysterectomies. *J Indian Med Assoc* 2002; 100: 238-46.
6. Sarfraz J, Tariq H. Histopathological finding in menorrhagia. A study of 100 hysterectomy specimens. *Pak J Pathol* 2005; 16: 83-5.
7. Ahsan S, Naeem S, Ahsan A. A case notes analysis of hysterectomy performed for non neoplastic indications at Liaquat National Hospital, Karachi. *J Pak Med Assoc* 2001; 51: 346-9.
8. Kamal F, Farrukh R, Khalid AW, Ghazal S, Naheed F, Afsar A. Pattern and frequency of various uterine tumours: A Retrospective study over a period of 26 months. *Biomedica* 2003; 19: 36-39.
9. Marino JL, Eskenazi B, Warner M, Samuels S, Vercellin P, Gavoni et al. Uterine leiomyoma and menstrual characteristics in a population – based cohort study. *Hum Reprod* 2004; 19: 2350-55.
10. Victory R, Romano W, Benett J, Diamond MP. Uterine leiomyomas. In: Bieber EJ, Sanfilippo JS, Horowitz IR, editors. *Clinical Gynecology*. Churchill Livingstone; 2006: p. 179.
11. Katz VL. Benign Gynecologic lesions. In: Katz VL, Leutz GM, Lobo RA, Gershenson DM, editors. *Comprehensive Gynecology*. 5th ed. Mosby: 2007: p. 436-49.
12. Cramer SF, Patel A. The frequency of uterine leiomyomas. *Am J Clin Pathol* 1990; 94: 435-8.
13. Luqman M, Bukhari L. Abnormal / excessive uterine hemorrhage, A histopathological study. *Pak J Pathol* 1998; 9: 20-4.
14. Bergholt T, Eriksen L, Berendt N, Jacobsen M, Hertz JB. Prevalence and risk factors of adenomyosis at hysterectomy. *Hum Reprod* 2001; 16: 2418-21.
15. Shaikh H, Khan KS. Adenomyosis in Pakistani women: four year experience at the Agha Khan University Medical Centre, Karachi. *J Clin Pathol* 1990; 43: 817-19.
16. Rosai J. Female reproductive system. In: Rosai and Ackerman's, editors. *Surgical Pathology (Vol II)*. 9th ed. Mosby. An imprint of Elsevier; 2004: p. 1524.
17. Parazzini F, Mais V, Cipriani S, Busacca M, Venturini P, Civattini A. Determinants of adenomyosis in women who underwent hysterectomy for benign gynecological conditions: results from a prospective multicentric study in Italy. *Eur J Obstet Gynaecol Reprod Biol* 2009; 143: 103-6.
18. Talukder SI, Haque MA, Huq MH, Alam MO, Roushan A, Noor Z et al. Histopathological analysis of hysterectomy specimens, Mymensingh J 2007; 16: 18-24.