

CORPORA AMYLACEA IN HUMAN CADAVERIC BRAIN AGE RELATED DIFFERENCES

AYESHA MAQBOOL AND M. TAHIR

Department of Anatomy, University of Health Sciences, Lahore, Pakistan

ABSTRACT

The present study was designed to investigate the age related deposits of corpora amylacea (CA) in the human cadaveric brain. It is an observational study which was conducted in the Department of Anatomy, University of Health Sciences, Lahore. The duration of the study was two years. Sixty brain specimens (age 19-72 years) from cadavers were collected from the mortuary of the King Edward Medical University, Lahore and were divided into two groups, A and B comprising less than and more than sixty years of age respectively. CA were observed in memory related areas of the brain specially in frontal lobe and hippocampus. The presence and location of CA in two groups were compared with each other. Statistical analysis was carried out, using Chi Square test. The results showed significant increase in the presence of CA in frontal lobe and hippocampus with advancing age and the difference was statistically significance in these locations ($p < 0.00005$ and $p < 0.0001$) respectively. The presence and number of CA is age related; it is contended that it interferes with the function of neurons and presumably affects the memory.

Key Words: *Corproa, Amylacea, Brain, Age.*

INTRODUCTION

Various neurodegenerative age related conditions, Parkinson's, Alzheimer's, picks and Huntington's diseases are characterized by presences of Corpora amylacea which also occur per se with advancing age; corpora amylacea are spherical, basophilic structures which normally accumulate in perivascular and subpial regions of the brain;¹ these commonly originate within astrocytic processes, although neuronal and oligodendroglial origin has also been reported.^{2,3}

The aetiology of CA is not properly understood; since these inclusions are products of degeneration and usually develop in the ageing brain, it is presumed that chronic local cellular stress might be responsible for their formation and development.⁴ Chemically CA are composed of glucose polymers 88%, protein 5% and phosphate 3%; their protein components consist of ubiquitin congregates⁵ and Nestin filaments which are their essential structural part and are formed in higher concentration in the brain with advancing age especially after forty years.⁶

Present study was designed to investigate age of appearance of CA in the brain, their quantitative and qualitative changes with advancing years of the subjects; on the presumption that the result of their increasing number with advancing age might offer some explanation of interference in the memory functions of the brain.

MATERIAL AND METHODS

Sixty brain specimens were obtained during post mortem examination of cadavers at Department of Forensic Medicine and Toxicology, King Edward Medical University Lahore; the brains were removed within 48 hours of the death of the subjects and immediately immersed in 10% neutral formalin. A written consent from the close relation of the deceased was also obtained in each case.

After a week, two centimeter thick pieces were sliced in a coronal plane using both right and left cerebral hemispheres; superior frontal gyrus and hippocampus were used for the investigations. Accordingly, 4 mm³ pieces of brain were obtained perpendicular to the cortical surface; these were then placed in individual tissue cassettes which also included the description giving the identification of the specimen. The material was processed in automatic tissue processor and paraffin blocks were prepared. 10µm thick sections were cut, using rotary microtome (Leica RM 2125); six slides, each having two sections, were prepared from each block.; these were treated with H and E stains for general histological study and PAS was employed for highlighting the morphology of CA. The sections were mounted with DPX and examined under Leica 1000 DM microscope.

STATISTICAL ANALYSIS

A SPSS soft ware package (SPSS Inc, Chicago, IL, USA) was used to perform statistical calculations.

Chi Square test for independent samples was applied to compare the possible difference between groups.

RESULTS

Our investigations showed sparsely occurring and small in sized CA in seven cases of hippocampus and eight in frontal lobe from group A whereas group B revealed evidence of CA larger in size from fifteen cases of hippocampus and thirteen of frontal lobe. Comparison of numbers between two groups showed a statistically significant difference ($p = 0.00005$, Table 1, Figure 1).

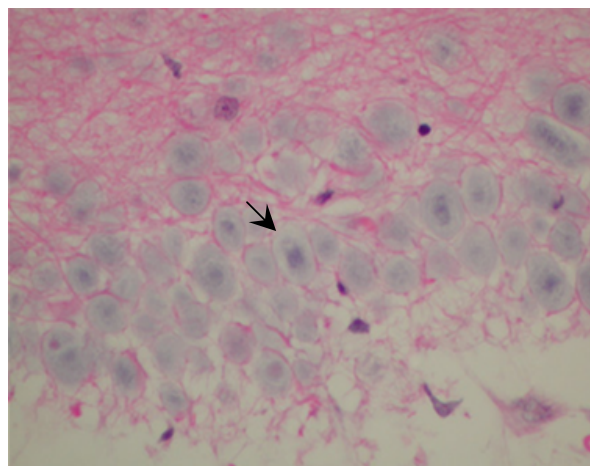


Fig. 1: Photomicrograph of cerebral cortex from group B, showing corpora amylacea (Black arrow); H & E stained X200.

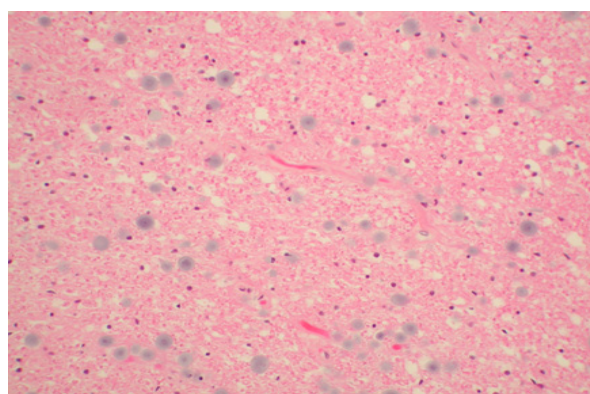


Fig. 2: Photomicrograph of cerebral cortex from group B showing corpora amylacea; H & E stained X100.

Table 1: Corpora Amylacea in Sixty Autopsy Cases (Hippocampus vs Frontal Lobe).

Group	Hippocampus		Frontal Lobe	
	Positive	Negative	Positive	Negative
Group A (42 cases)	7	35	8	34
Group B (18 cases)	15	3	13	5

(Figures in parentheses indicate total number in each group. Chi Square test was applied)

$p < 0.05$ is statistically significance.

Hippocampus: Group A vs Group B: $p < 0.00005$.

Frontal Lobe: Group A vs Group B: $p < 0.0001$.

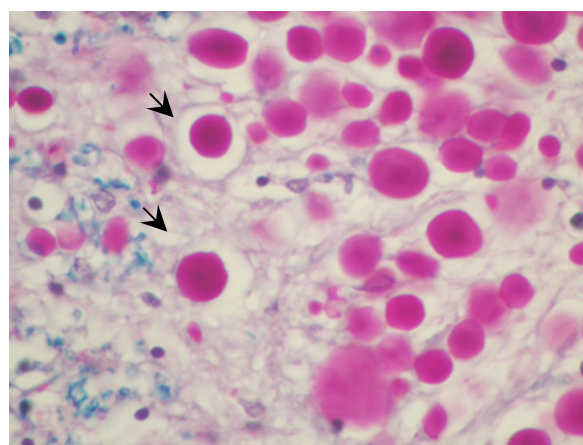


Fig. 3: Photomicrograph of hippocampus from group B showing corpora amylacea (black arrow) in periventricular area. PAS stain X 200.

DISCUSSION

Various neurodegenerative age related conditions, Parkinson's, Alzheimer's and picks and Huntington's diseases, the are conditions of unknown aetiology and are characterized by presences of Hirano, Lewy bodies, Corpora amylacea and neurofibrillary tangles³ which increase with advancing age. Our observation confirms that CA develops in aging brain characterizing a its chronic degenerative conditions. It had been reported that stressful conditions in life produce repetitive and chronic local cellular strains participate in formation and growth of CA.⁶ Virchow introduced the term of Corpora amylacea (CA) for the round bodies in the aging brain for their resemblance to starch granules which stained brown instead of blue with iodine. In present study the corpora amylacea were observed as small globular formations and concretions, primarily located at the subpial region of the superior frontal gyrus and periventricular are-

as, although these had also been reported to occur in other organs such as lungs,^{7,8} uterus,⁷ prostate,⁹ eyes¹⁰ and pineal gland.¹¹ Schipper reported that CA present around the periventricular regions had affinity for PAS which increased with advancing age.³ Our observations agree with the earlier findings that CA formation increases with age and develop affinity for PAS. Similarly Fawcett⁸ stated that CA appeared initially between the third and fifth decades of the life and become more frequent in old age.¹²

In present work it was seen that CA appeared as concentric and lamellar a cellular eosinophilic material which showed variable staining intensities with increasing age. In certain H and E stained slides it was observed that small size CA showed darker staining reactions as compared to those larger in size; the darker staining of small sized CA was presumably on account of their compact structure as compared to the larger ones which appeared to be in concentric, lamellated and fibrillar structure, increasing with age. *Drachenberg* and *Papadimitriou*⁸ studied the ultra structure of the CA and observed that those consisted of concentric and fibrillar bands with occasional small electron-dense polymorphic areas between the fibrils⁹. Biochemically the CA were found to belong to amyloid substance, β -2-microglobulin which composed of more carbohydrate than protein (2:1), high concentration of sugars (glucosamine, galactose) and sulphur, suggesting presence of glycosaminoglycans.¹³

Currently the origin and function of CA is debated. It is reported that CA and amyloid substance, both accumulate simultaneously as a consequence of senile degenerative process of the epithelium.^{14,15} On the other hand, *Cohan*¹³ concluded that CA is the final consequence of glandular secretion and accumulation of cellular debris.¹³ Our observations are in accord with those of *Cohan* who reported that CA usually accumulates as a result of ageing process in periventricular space and under subpial region of the brain. Our data indicated that CA are age related phenomena. In Present study, we also observed that the shape and size of the CA changed with the increasing age. Initially CA appeared as small, compact circular deeply basophilic structures; but with the advancement of age they changed to lightly stained, large concentric whorls. Their number significantly increased around the periventricular space and under subpial region with increasing age and this increase was statistically significant ($p < 0.0001$, $p < 0.00005$) respectively.

It is **concluded** the result of this study suggests that the deposition of CA is age related and appears earlier in hippocampal region, which asso-

ciated with memory; it may be responsible for serious memory impairment related with age.

ACKNOWLEDGEMENT

The authors are thankful to Professor Malik Hus-sain Mubbashar, the Vice Chancellor of University of Health Sciences Lahore Pakistan, for providing facility to carry out this work. We must thank Miss Bushra for providing technical assistance.

REFERENCES

1. Erdamar S, Zhu ZQ, Hamilton WJ. Corpora Amylacea and heat shock protein 27 in Ammon's horn sclerosis. *J Neuropathol Exp Neurol* 2002; 59: 698-706.
2. Riberio M, Coutinho L, Mugnol F, Hilbig A, Palmi A, Costa J et al. Corpora amylacea in temporal lobe epilepsy associated with hippocampal sclerosis. *Arq Neuropsiquiatr* 2003; 61 (4): 942-945.
3. Schipper HM, Cissé S. Mitochondrial constituents of corpora amylacea and autofluorescent astrocytic inclusions in senescent human brain. *Histol Histopathol* 2004; 14 (1): 55-64.
4. Gati I, Ossy L. Heat shock protein 60 in corpora amylacea. *Pathology oncology research* 2001; 7 (2): 140-144.
5. Hoyaux D, Decaestecker C, Heizmann CW, Vogl T, Schafer BW, Salmon I et al. S100 proteins in corpora amylacea from normal human brain. *Brain Res* 2000; 867: 280-8.
6. Buervenich S, Olson L, Galter D. Nestin like immunoreactivity of corpora amylacea in aged human brain. *Brain Res Mol* 2001; 94 (1-2): 204-8.
7. Rocken C, Linke RP, Saeger N. Corpora amylacea in the lungs, prostate and uterus. A comparative and immunohistochemical study. *Pathol Res Pract* 1996; 192: 998-1006.
8. Yamanouchi H, Yoshinouchi T, Watanabe R, Fujita, Takahara J, Ohtsuki Y. Immunohistochemical study of a patient with diffuse pulmonary corpora amylacea detected by open lung biopsy. *Inter Med* 1999; 38: 900-903.
9. Drachenberg CB, Papadimitriou JC. Prostatic corpora amylacea and cristalloids: similarities and differences on ultrastructural and histochemical studies. *J Submicrosc Cytol Pathol* 1996; 28: 141-150.
10. Avendano J, Rodrigues M, Hackett J, Gaskins R. Corpora amylacea of the optic nerve and retina: a form of neuronal degeneration. *Investigative ophthalmology and visual sciences* 1980; 19 (5): 550-555.
11. Koshy S, Vettivel S K. Varying appearance of calcification in human pineal gland: A light microscopic study. *J Anat. Soc. India* 2001; 50 (1): 17-18.
12. Fawcett DW, Leak LV. *Hand book of Physiology, Section 7, Endocrinology, Vol. 5, Male Reproductive System.* Baltimore, Williams and Wilkins, 1975: Pp. 57-94.
13. Cohan RJ, McNeal JE, Redmond SL, Meehan K, Thomas R, Wilce M, Dawkins HJ. Luminal contents of benign and malignant prostatic gland: correspondence to altered secretory mechanisms. *Hum Pathol* 2000, 31: 94-100.

14. Cross PA, Bartley CJ, Mc Clure J. Amyloid in prostatic corpora amylacea. *J Clin Pathol* 1992, 45:894-897.
15. Morales E, Polo L, Pastor L, Santamaria L, Calvo A, Zuasti A et al. Characterization of corpora amylacea glycoconjugates in normal and hyperplastic glands of human prostate. *Journal of molecular histology* 2005, 36: 235-242.